

CHAPTER **e12**

Atlas of Oral Manifestations of Disease

Samuel C. Durso
Janet A. Yellowitz

The health status of the oral cavity is linked to cardiovascular disease, diabetes, and other systemic illnesses. Thus, examining the oral cavity for signs of disease is a key part of the physical exam. This chapter presents numerous outstanding clinical photographs illustrating many of the conditions discussed in [Chap. 32](#), Oral Manifestations of Disease. Conditions affecting the teeth, periodontal tissues, and oral mucosa are all represented.

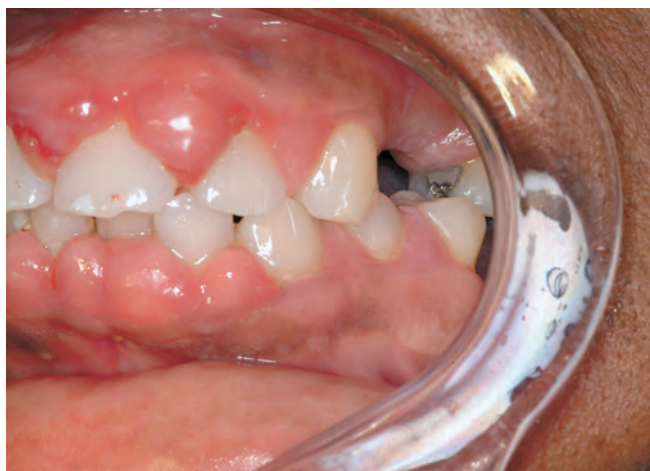

Figure e12-1 Gingival overgrowth secondary to calcium channel blocker use.

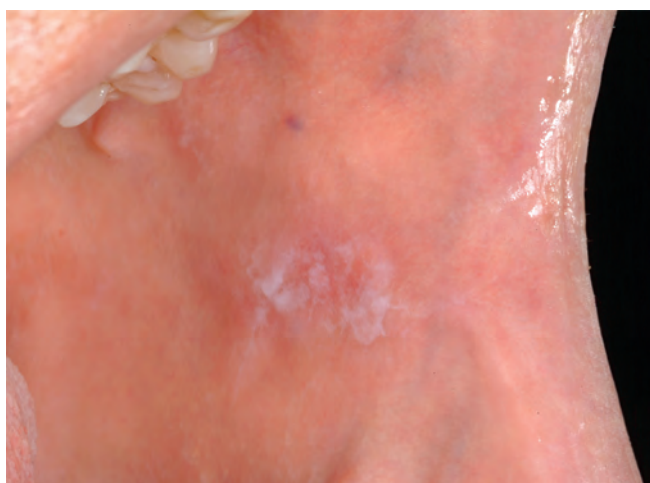


Figure e12-2 Oral lichen planus.

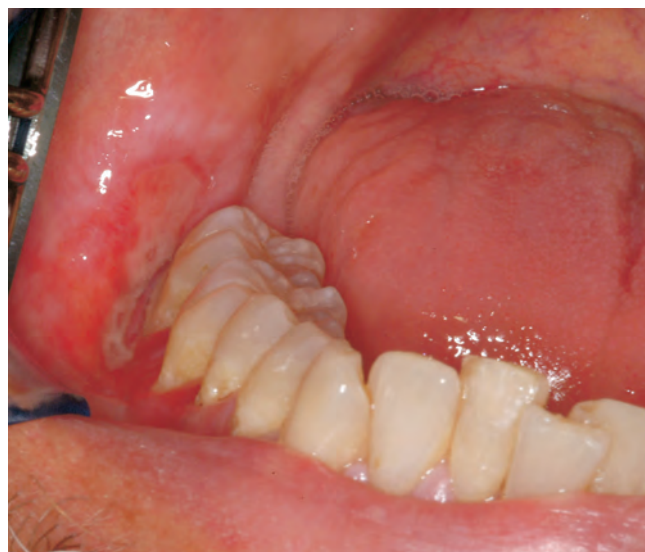

Figure e12-3 Erosive lichen planus.

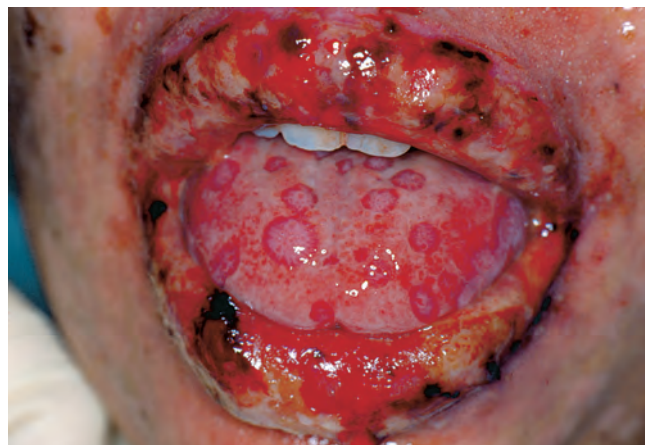

Figure e12-4 Stevens-Johnson syndrome—reaction to nevirapine.

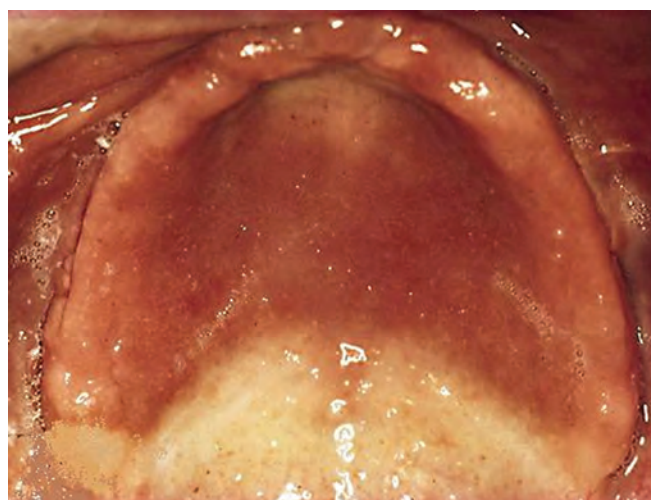


Figure e12-5 Erythematous candidiasis under a denture (i.e., the patient should be treated for this fungal infection).

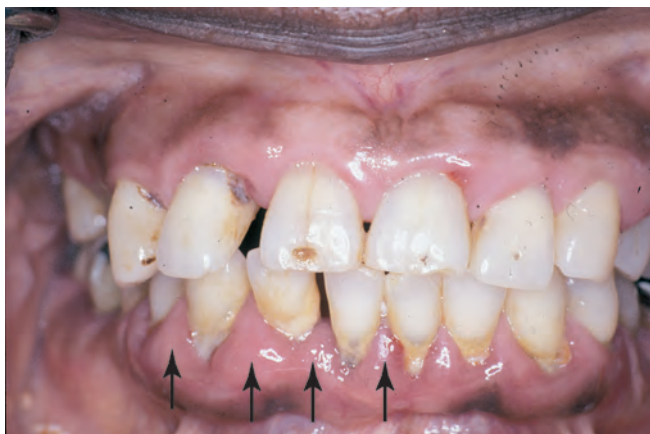

Figure e12-6 Severe periodontitis.

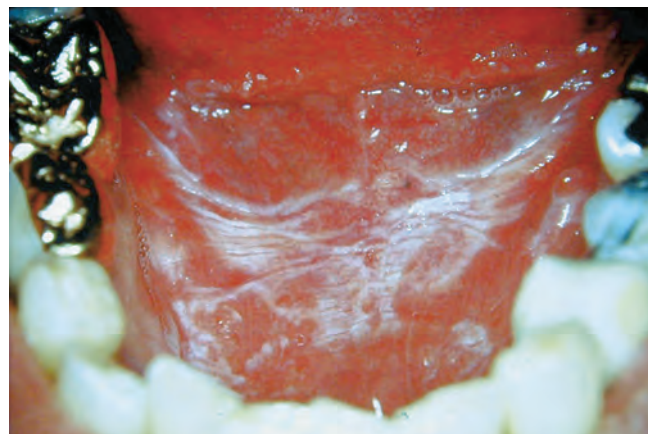


Figure e12-8 Sublingual leukoplakia.

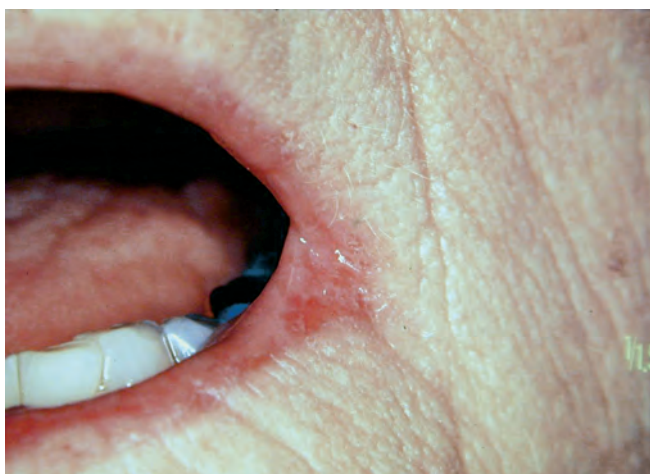
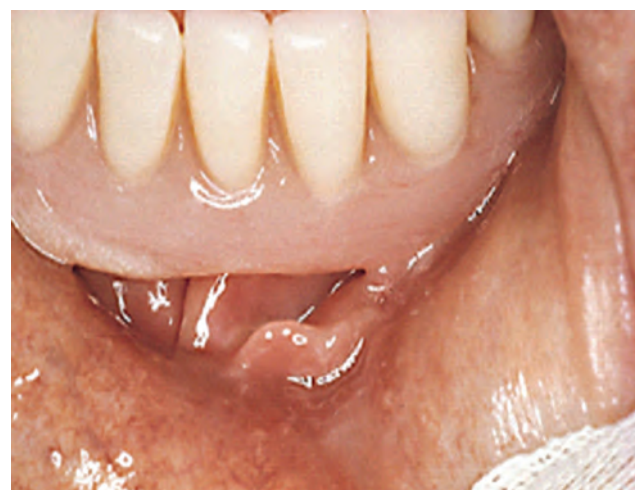
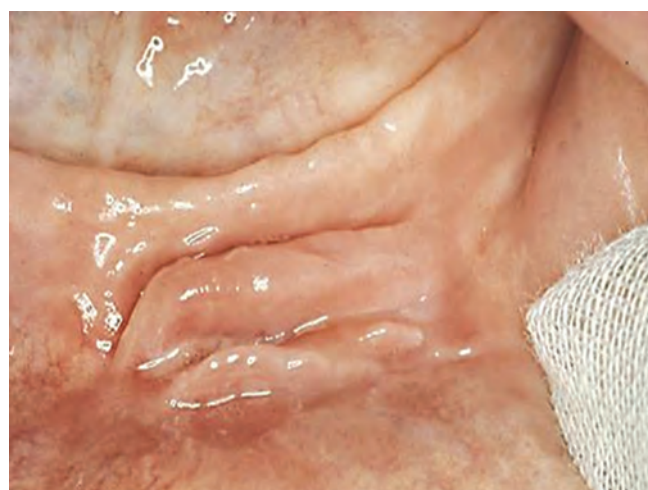Figure e12-7 Angular cheilitis.



A



B

Figure e12-9 **A.** Epulis (gingival hypertrophy) under denture. **B.** Epulis fissuratum.

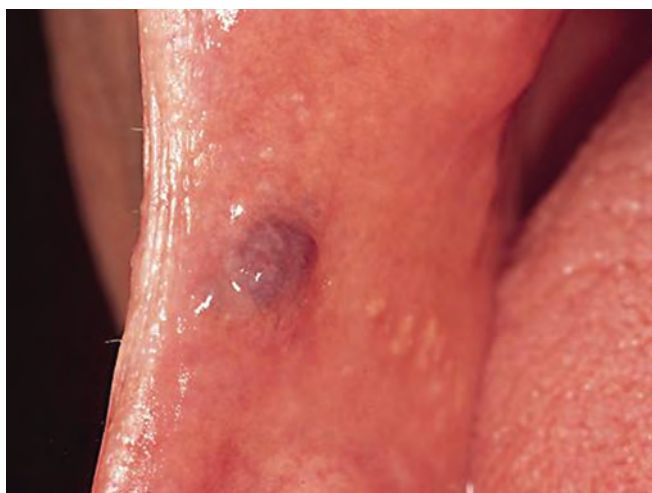

Figure e12-10 Traumatic lesion inside of cheek.

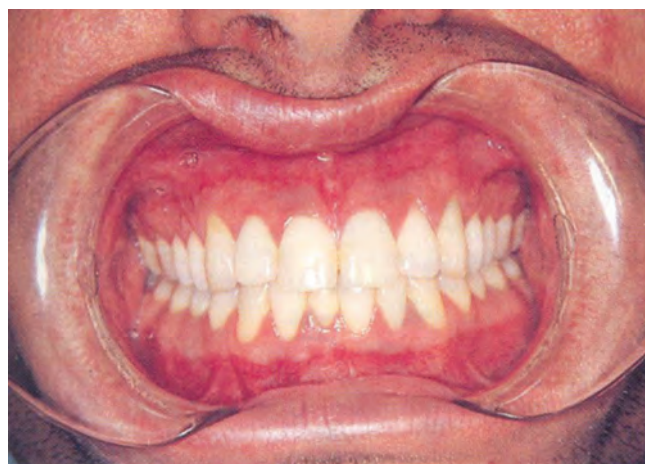

Figure e12-13 Healthy mouth.

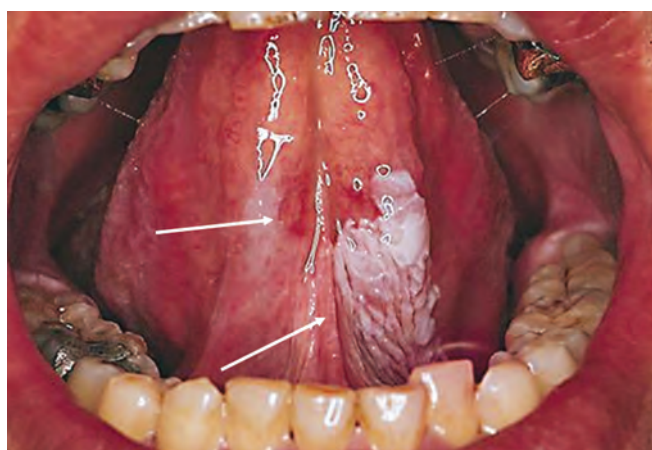


Figure e12-11 Oral leukoplakia, subtype homogenous leukoplakia.

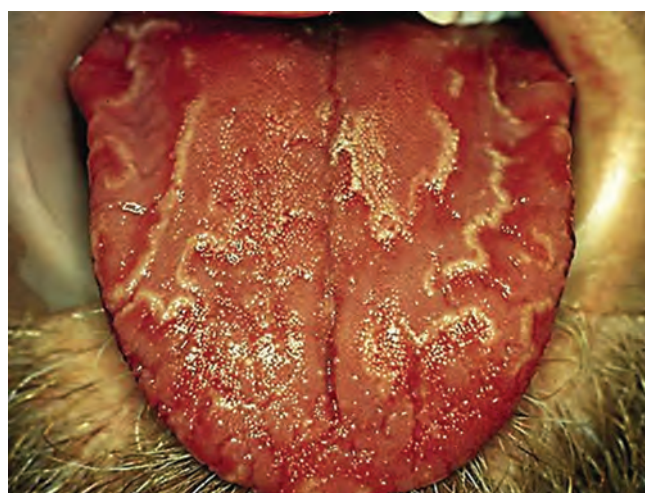


Figure e12-14 Geographic tongue.

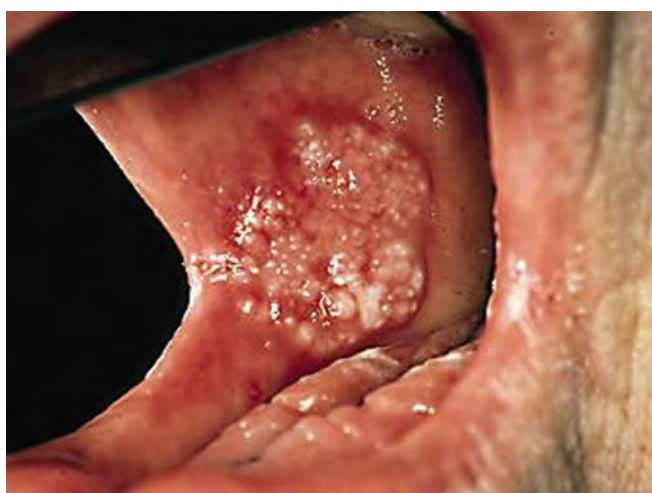

Figure e12-12 Oral carcinoma.

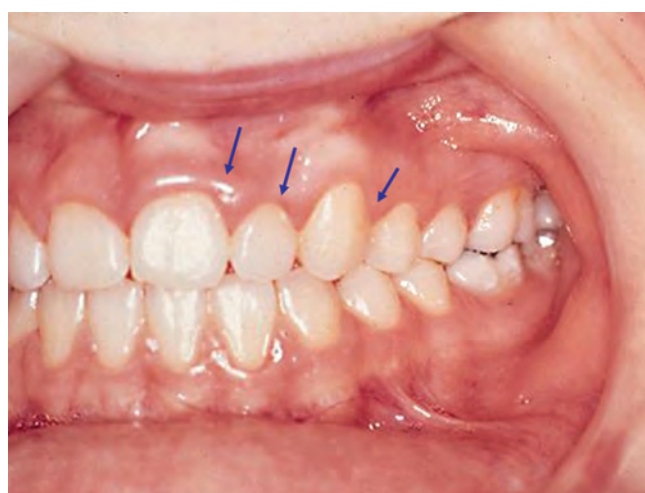

Figure e12-15 Moderate gingivitis.

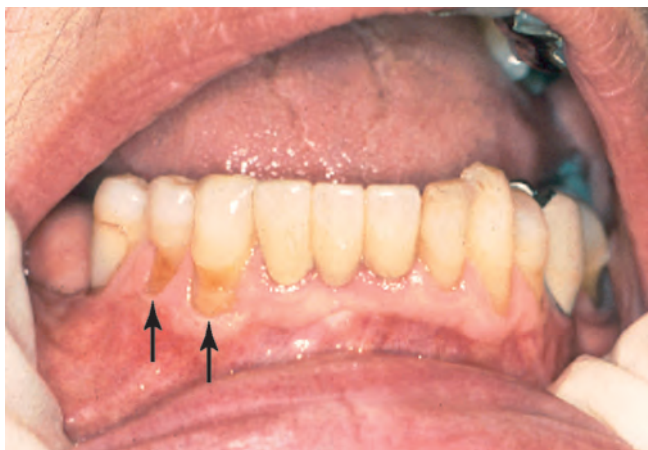

Figure e12-16 Gingival recession.

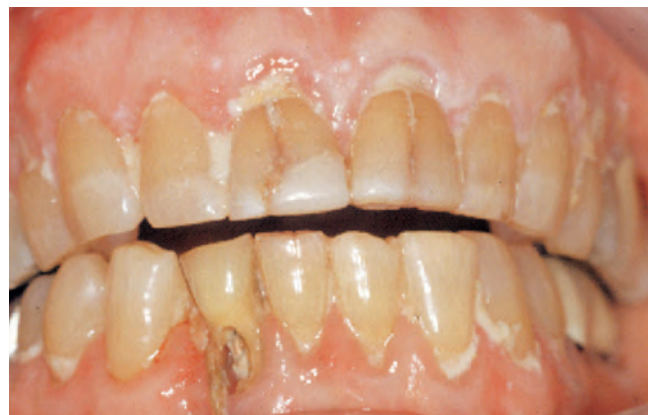

Figure e12-19 Root cavity in presence of severe periodontal disease.

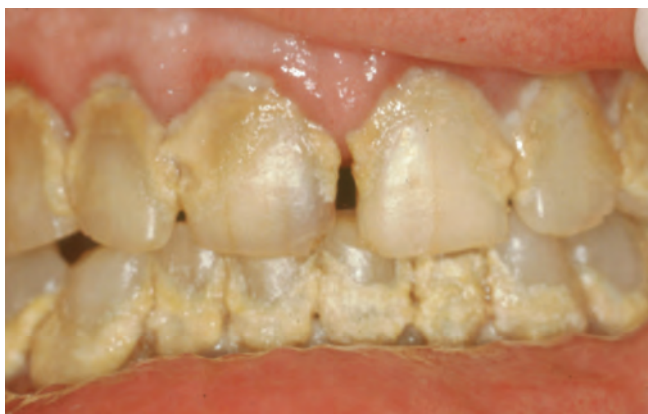

Figure e12-17 Heavy calculus and gingival inflammation.

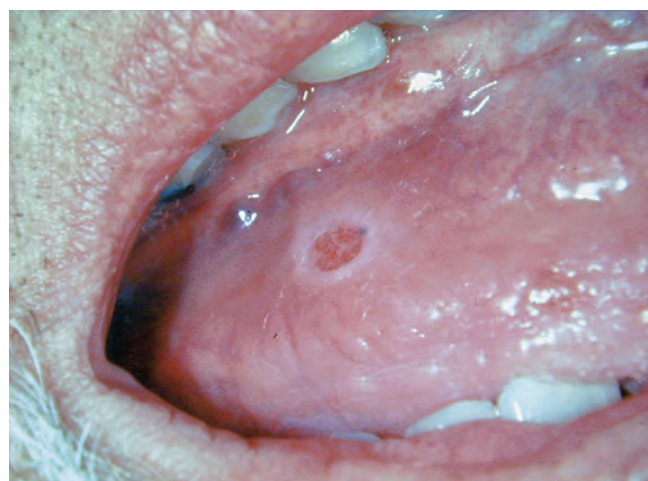

Figure e12-20 Ulcer on lateral border of tongue—potential carcinoma.

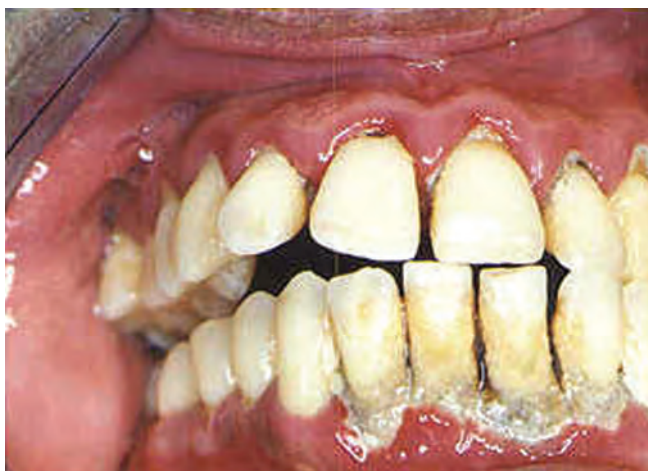

Figure e12-18 Severe gingival inflammation and heavy calculus.

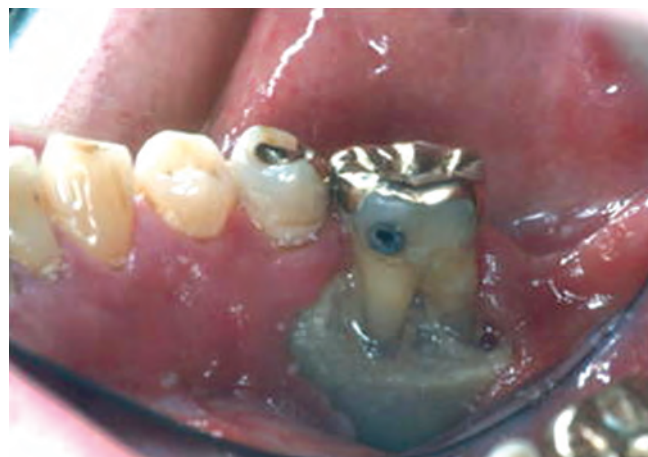

Figure e12-21 Osteonecrosis.

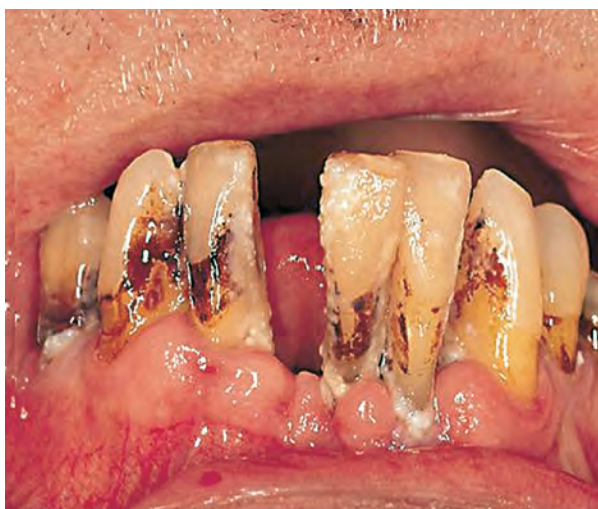

Figure e12-22 Severe periodontal disease, missing tooth, very mobile teeth.

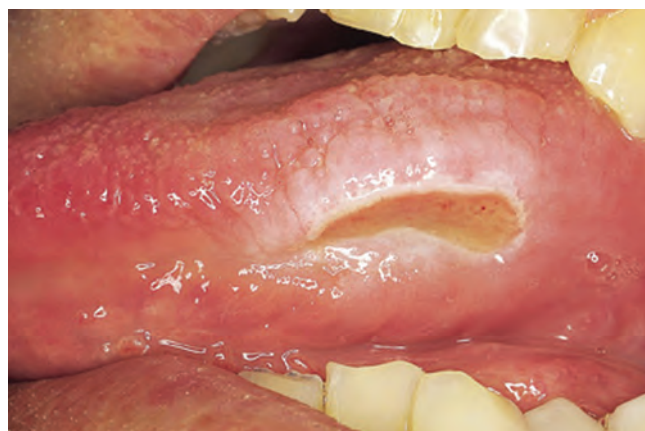

Figure e12-25 Traumatic ulcer.

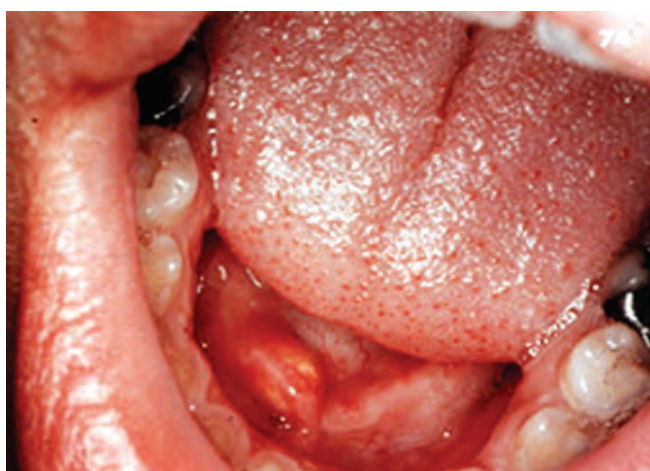

Figure e12-23 Salivary stone.

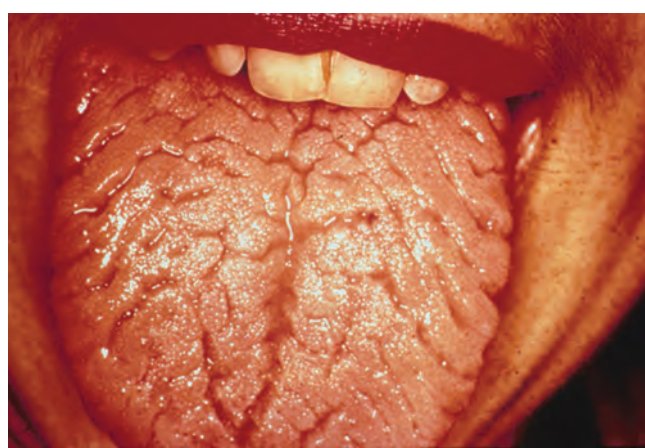


Figure e12-26 Fissured tongue.

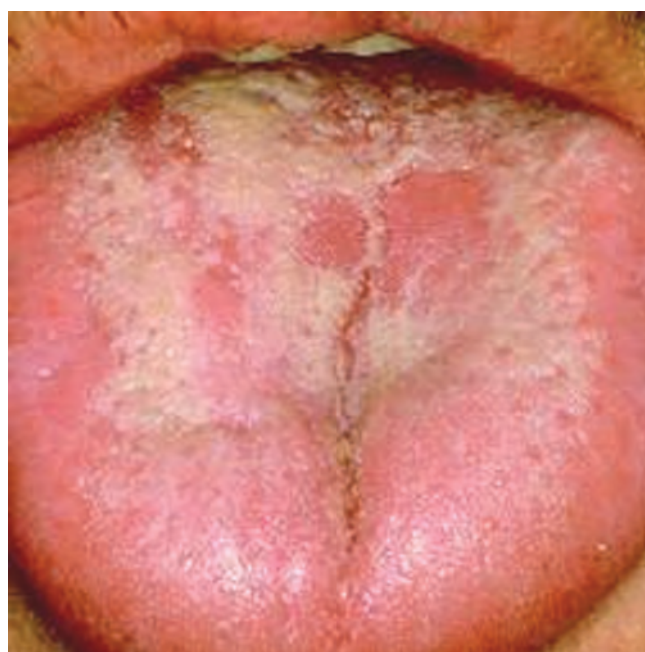

Figure e12-27 White coated tongue—likely candidiasis.

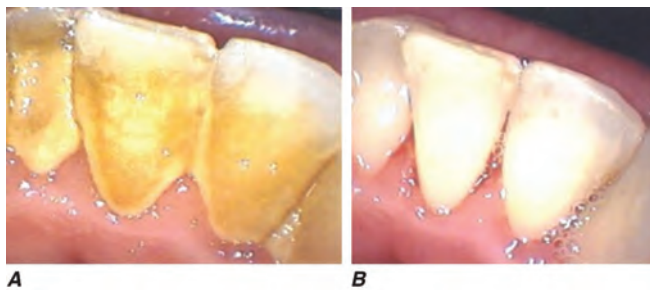


Figure e12-24 A. Calculus. B. Teeth cleaned.

ACKNOWLEDGMENT

Dr. Jane Atkinson was a co-author of this chapter in the 17th edition. Some of the materials have been carried over into this edition.

