



Chapter I

BASIC PRINCIPLES OF ECG INTERPRETATION

Cardiac rhythm analysis may be accomplished informally via cardiac monitoring and more diagnostically via a 12-lead electrocardiogram (ECG). An electrocardiogram is a recording of waveforms that reflects the electrical activity of the heart. Cardiac monitoring can depict the electrical impulse flow between two leads at one time, while a 12-lead ECG can provide information about the electrical impulse flow from 12 different views of the heart.

DEPOLARIZATION AND REPOLARIZATION

As an electrical impulse flows through the heart, a process of depolarization and repolarization occurs with each beat of the heart. Depolarization is considered to be the action state, and repolarization is the resting state. During depolarization and repolarization, four main electrolytes (sodium, potassium, calcium, and chloride) move across the cardiac cell membrane. Five cycles of movement occur during this depolarization/repolarization process. In Phase 0 or rapid depolarization, an impulse is received by the cardiac cell that stimulates the rapid movement of sodium into the cell and a slower movement of calcium into the cell. In Phase 1 or early repolarization, the sodium channels close and sodium movement stops. In Phase 2 or the plateau phase, the calcium continues to move into the cell and potassium starts to move out of the cell. During Phase 3 or the rapid

2 Nurse to Nurse: ECG Interpretation

repolarization phase, the calcium channels close and potassium moves quickly out of the cell. Up until the middle of Phase 3, the cardiac cell is in an absolute refractory period and unable to respond to an electrical stimulus. At the end of Phase 3, a strong impulse could initiate a beat as the cell is now in its relative refractory period. While in Phase 4 or the resting phase, the sodium/potassium pump starts to return potassium intracellularly and move sodium extracellularly. At the end of this phase, the cell is ready to begin the process all over again. The process of depolarization and repolarization creates an electrical field and flow of electrical current that can be portrayed on an ECG.

CHARACTERISTICS OF CARDIAC CELLS

Cardiac cells have characteristics that make the heart function continuously and rhythmically. The five main characteristics are automaticity, excitability, conductivity, contractility, and refractoriness.

Automaticity

Automaticity is the ability of the cardiac muscle cells to initiate an electrical impulse without being stimulated by a nerve or other source. Most cells within the heart have this capability; yet the normal site of automaticity is the sinoatrial (SA) node. Normal electrolyte balance maintains the automaticity within the sinoatrial node. Lower levels of potassium and calcium may increase the automaticity of cardiac cells within other areas of the heart, leading to the development of extrasystolic beats or “funny-looking beats” that originate in sites other than the sinoatrial node.

Excitability

Excitability is the ability of the cardiac cells to respond to an electrical stimulus. At times, cardiac cells may become highly irritable or excitable from electrical, mechanical, or chemical sources. The increase in irritability leads to a lower stimulus threshold needed for the heart to contract. For example, the

chemical effect of a low pO_2 or hypoxia may make the ventricular tissue more irritable or excitable.

Conductivity

Conductivity is the ability of cardiac cells to receive an electrical impulse and transmit the impulse to an adjacent cardiac cell. All cells within the heart have this capability due to the presence of intercalated discs located within the cardiac cell membrane. Conductivity of cardiac cells provides the mechanism for impulses to travel throughout the myocardium. So once the impulse is initiated through the automaticity feature of cardiac cells, now the impulse can travel throughout the myocardium. A couple of components that may affect the conductivity of the cardiac cells can be parasympathetic/sympathetic stimulation and medications. For example, parasympathetic stimulation can slow down the conductivity of the impulse, while sympathetic stimulation may speed up the conductivity of the impulse.

Contractility

Contractility is the ability of the myocardium to shorten its muscle fibers in response to the conducted electrical stimulus. The shortening of the muscle fibers results in contraction of the atria and the ventricles, producing forward movement of blood through the heart and into the body's periphery, generating a pulse. The strength of the contraction may be altered by positive or negative inotropic drugs, which increase or decrease the force of the muscle contraction. For example, digoxin is a positive inotropic agent that increases the force of contraction by inhibiting the sodium/potassium pump. Diltiazem is a negative inotropic agent that decreases the force of contraction by blocking the action of the calcium in the actin-myosin filaments of the muscle cells.

Refractoriness

The refractory period is the length of rest time needed after the depolarization period and contraction of the muscle. In cardiac

4 Nurse to Nurse: ECG Interpretation

cells, three refractory periods are differentiated to correspond with the heart's ability to respond to a subsequent electrical stimulus: absolute, relative, and supernormal. An absolute refractory period is the time period between the beginning of the QRS complex to the T wave peak, which envelops the initial phases of the cardiac action potential including Phases 0, 1, 2, and part of 3. During the absolute refractory period, the cardiac cell is totally unable to respond to an electrical stimulus with cellular depolarization or contraction. The relative refractory period occurs during the downward slope of the T wave, when some cardiac cells have repolarized, yet other cardiac cells are in the process of repolarization. At this point in time, cardiac cells can depolarize and immediately initiate another beat only when the electrical stimulus is much stronger than the usual electrical stimulation needed to create a beat. An example of a beat originating during this time period is a premature ventricular contraction with an R-on-T phenomenon. The supernormal refractory period occurs at the end of the T wave. During the supernormal period, a weaker electrical stimulus can initiate depolarization and cardiac contraction. Examples of the beats originating during the supernormal refractory period include extrasystolic beats such as premature atrial contractions, premature junctional contractions, and premature ventricular contractions.

MECHANICAL EVENTS

The waveforms seen on an ECG normally reflect simultaneous mechanical events. The presence of a P wave is associated with contraction of the atria. The presence of a QRS complex is associated with ventricular contraction while a T wave is associated with ventricular muscle relaxation. The electrical events associated with atrial relaxation are not visible on an ECG. The mechanical events and electrical events in combination determine the amount of blood leaving the left ventricle to be pumped into the aorta and throughout the vascular system of the body. The amount

of blood ejected from the left ventricle per minute is called the cardiac output. A normal cardiac output is 4 to 8 L/min. The cardiac output equals the heart rate times the stroke volume. The stroke volume is the amount of blood ejected from the ventricles per minute—normally about 70 mL/beat. The stroke volume may be affected by three main factors: preload, afterload, and myocardial contractility. Preload is the ability of the myocardial muscle to stretch and contract at the end of diastole. Afterload is the amount of vascular resistance or pressure the heart needs to exert to push the blood out of the ventricular chambers into the pulmonary or systemic vascular system. Myocardial contractility is the force of ventricular contraction, which is dependent on the amount of stretch of the ventricular fibers.

CARDIOVASCULAR BLOOD FLOW

The heart is a muscular organ with three layers: endocardium (inner lining of the heart), myocardium (muscular layer), and epicardium (outer lining of the heart). Surrounding the heart is a thin membranous sac with approximately 5 to 30 mL of pericardial fluid called the pericardial sac. These tissues of the heart function to move the blood forward in a smooth contraction during the systolic phase of the cardiac action potential. The

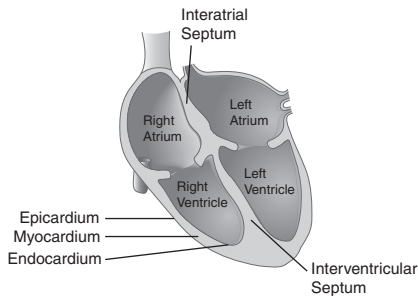


Figure 1-1 Heart anatomy.

forward movement of the blood forces the blood to move from the superior and inferior venae cavae to the right atrium through the tricuspid valve and into the right ventricle. Depolarization of the right ventricle moves the blood through the pulmonic valve into the pulmonary artery and out to the lungs. After oxygenation occurs in the pulmonary system, the blood returns to the heart via the pulmonary vein into the left atria. Depolarization of the left atria moves the blood through the mitral valve into the left ventricle. The left ventricle is considered to be the powerhouse of the heart, as it is responsible for moving the blood through the aortic valve out to the aorta and the remaining vessels within the body (Fig. 1-1).

CARDIAC REGULATION

The electrical conduction system of the heart is regulated by the autonomic nervous system. The autonomic nervous system is composed of the sympathetic and the parasympathetic nervous systems. The parasympathetic nervous system releases acetylcholine, which affects the heart by reducing the number of electrical impulses being initiated, thus decreasing the heart rate. Parasympathetic stimulation predominantly affects the SA and AV (atrioventricular) nodes. A reduced pulse rate may be caused by medications, such as beta blockers, and certain activities, such as vomiting, straining with bowel movements, and bladder distension. The sympathetic nervous system stimulation releases norepinephrine, which affects the heart by increasing the number of electrical impulses being initiated, thus elevating the heart rate. Sympathetic stimulation may affect all areas of the heart. An increased pulse rate may be caused by medications, such as nitrates and caffeine, and certain conditions, such as pain, hypoxia, and anxiety.

ELECTRICAL CONDUCTION PATHWAY OF THE HEART

As noted earlier, any cardiac cell has automaticity and the ability to initiate an impulse in the heart. Yet, the normal pacemaker

site of the heart is the sinoatrial node. The conductivity of the heart normally follows an electrical pathway from the sinoatrial node through the interatrial pathway to the atrioventricular node to the bundle of His down the bundle branches to the Purkinje fibers (Fig. 1-2).

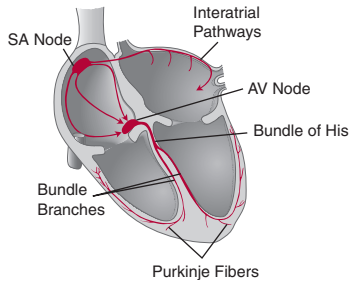


Figure 1-2 Normal conduction pathway of the heart.

Sinoatrial Node

The sinoatrial (SA) node is located in the upper posterior wall of the right atrium just distal to the opening from the superior vena cava. It is responsible for the normal pacemaker function of the heart. The SA node's automaticity initiates beats at a rate of 60 to 100 beats per minute (bpm) normally.

Interatrial and Internodal Pathways

The electrical impulse is normally conducted from the SA node through the interatrial pathway in the left atria to the AV node. The interatrial pathway in the left atria is also called the Bachmann bundle. The electrical impulse travels through the right atria via the anterior, middle, and posterior internodal pathways. These electrical pathways spread the impulse across the atrial muscle to the atrioventricular node.

Atrioventricular Node

The atrioventricular (AV) node is located in the right atrium behind the tricuspid valve. Junctional tissue surrounds the AV node. The AV node lacks automaticity and is unable to initiate an electrical impulse or heartbeat, but junctional tissue may initiate a rhythm with an inherent rate of 40 to 60 bpm. The AV node conducts the electrical impulse from the atria to the ventricles after delaying the transmission for approximately 0.04 seconds, which allows for the atria to contract and fill the ventricles.

Bundle of His

The electrical impulse travels rapidly from the AV node down the bundle of His, where the impulse splits into the right and left bundle branches.

Bundle Branches

The impulse moves down the right bundle branch along the interventricular septum and through the right ventricle. The impulse simultaneously moves down the left bundle branch along the interventricular septum and through the left ventricle. The bundle branch tissue may initiate an electrical impulse when the SA node and atrial tissue fail to pace the heart. The inherent rate of bundle branch impulses is 40 to 60 bpm.

Purkinje Fibers

The Purkinje fibers are located in the ventricular walls of the heart. The electrical impulse travels from the right and left bundle branches through the Purkinje fibers to the ventricular cells. The ventricular tissue may initiate an electrical impulse when the SA node, atrial tissue, and junctional tissue fail to pace the heart. The inherent rate of ventricular impulses is 20 to 40 bpm.

12-LEAD ECG: LIMB AND CHEST

A 12-lead ECG provides multiple electrical views of the heart along a frontal and a horizontal plane. All 12 leads are useful when diagnosing a myocardial infarction, but for most cardiac monitoring

situations leads II, V_1 , and V_6 will be typically viewed. Limb leads are obtained through the use of four electrodes and include the standard and the augmented leads. The four electrodes are placed on the right arm, right leg, left arm, and left leg. Six electrical views of the heart may be seen using these four electrodes: I, II, III, aVR, aVL, and aVF. The standard limb leads—lead I, lead II, and lead III—use the right arm, left arm, and left leg, respectively. The augmented limb leads include aVR, aVL, and aVF, and use all four electrodes. Augmented leads are so-named because of the need of the ECG machine to magnify the waveforms to obtain an adequate tracing. The limb leads view the electrical activity of the heart along a frontal plane, from the top of the heart to the bottom of the heart, or from the right to the left of the heart. Chest leads are obtained with the use of six additional leads placed along the wall of the left side of the chest; these are identified as V_1 , V_2 , V_3 , V_4 , V_5 , and V_6 . Chest leads or precordial leads view the heart along the horizontal plane or cross-section from front to back of the body.

ECG machines tend to print 3 seconds of each lead in a standardized format with three rows of four columns. Column one includes leads I, II, and III. Column two includes aVR, aVL, and aVF. Column three includes V_1 , V_2 , and V_3 . Column four represents the remaining chest leads of V_4 , V_5 , and V_6 . Typically, lead II flows along the base of the 12-lead ECG.

ECG PROCEDURE: CARDIAC MONITORING AND 12 LEADS

Cardiac monitoring allows for 24-hour visualization of the patient's electrical activity within the heart, but typically limits the views of the electrical activity to two views at any one time. A 12-lead ECG permits viewing of 12 electrical positions in the heart, but is a cumbersome method for 24-hour monitoring. When monitoring a patient's electrical impulse flow through the heart with either cardiac monitoring or a 12-lead ECG, proper placement of the electrodes becomes essential to obtain accurate data. When placing the electrode on the chest, make sure the gel of the electrode is located on the designated area and be less concerned with placement of the entire electrode.

10 Nurse to Nurse: ECG Interpretation

Electrodes have better conduction when the patient's skin is washed and thoroughly dried before application of the electrode. Shaving hair from the planned electrode site will facilitate adhesion of the electrode to the skin.

Cardiac monitoring may be accomplished via a three- or five-lead system. A three-lead system includes a ground electrode plus a positive and negative electrode reflecting the limb leads on a 12-lead ECG. Any of the three limb leads may be read from this leadwire system, depending on how the operator adjusts the monitor settings (lead I, lead II, or lead III). Placement of the three-lead electrodes is displayed in Figure 1-3.

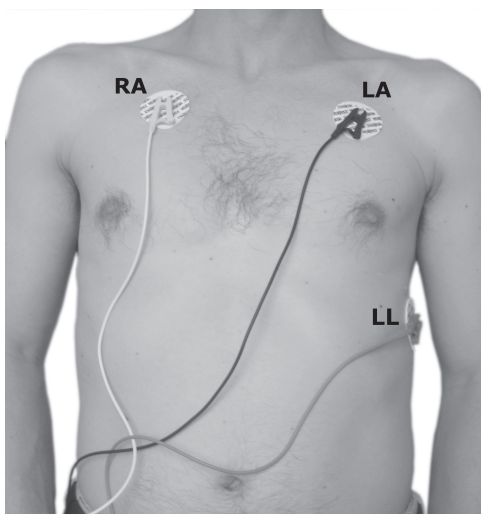


Figure 1-3 Three-leadwire electrode placement.

A second method of cardiac monitoring uses a five-leadwire system. The five-leadwire system allows for monitoring the limb leads and modified chest leads. Placement of the five-lead electrodes is shown in Figure 1-4. The five leadwires are color coded to improve accuracy of placement on the patient's chest: white (right arm), green (right leg), black (left arm), red (left leg), and

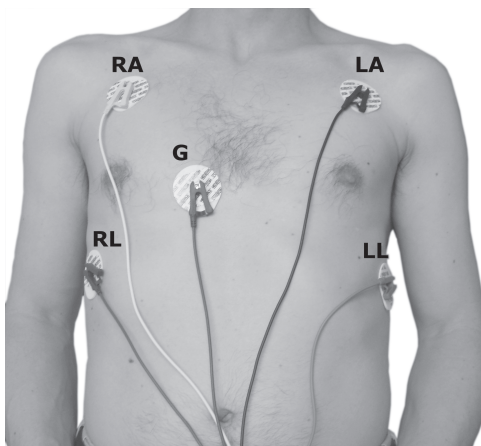


Figure 1-4 Five-leadwire electrode placement.

brown (fourth intercostal space near the right sternal border). Modified chest lead 1 (MCL_1) may be used by setting the monitor to use the brown ground lead as the positive electrode to simulate V_1 . Using the left leg lead as the positive electrode and the left arm as the negative electrode with the right arm as the ground electrode, the monitor may read a modified chest lead 6 (MCL_6) similar to V_6 . The modified chest leads can be beneficial in interpreting some dysrhythmias such as extrasystolic beats, identifying bundle branch blocks, and differentiating supraventricular tachycardia and ventricular tachycardia.



Tricks of the Trade

An easy way to remember placement of the color-coded electrodes for the five-leadwire system is “white on the upper right,” “snow on trees” (white above green), “smoke above fire” (black above red), and “chocolate’s close to the heart” (brown).

12 Nurse to Nurse: ECG Interpretation

The 12-lead ECG provides the most thorough ability to interpret electrical activity within the heart. In a 12-lead ECG, an electrode is placed on each upper arm and lower leg to monitor the standard leads (I, II, and III) and augmented leads (aVR, aVL, and aVF) along the frontal plane. In addition, chest leads may be used to evaluate the horizontal plane of electrical activity through assessment of V₁ to V₆. Placement of the electrodes on the arms, legs, and chest may be seen in Figure 1-5.

Location of the positive electrode for limb, augmented, and chest leads determines the view of the heart surface that may be

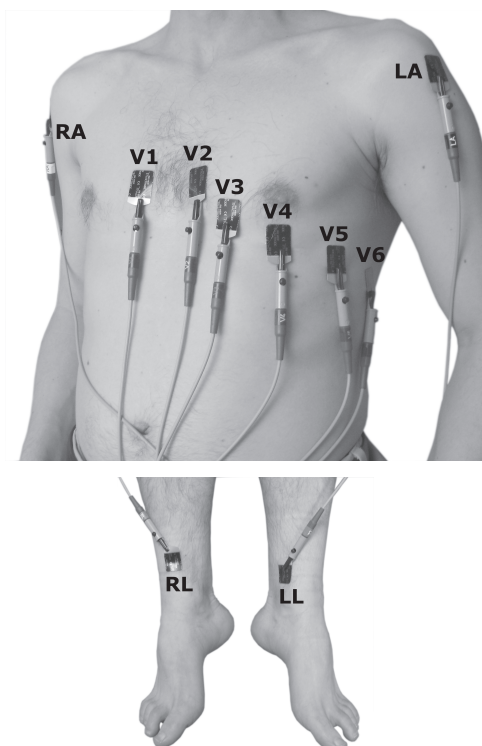


Figure 1-5 12-lead electrode placement.

observed in the ECG. For example, in lead I the positive electrode is located on the left arm which provides a view of the lateral surface of the left ventricle and displays a positively deflected R wave above the isoelectric line. The relationship of the limb, augmented, and chest lead placement site to the heart surface and ECG appearance is shown in Table 1-1.

Table 1-1 Relationship of Lead Placement Site to Heart Surface and ECG Appearance

	Lead	Positive Electrode Placement	View of Heart Surface	ECG Appearance
Standard Limb Leads	Lead I	Left arm	Lateral	QRS positive
	Lead II	Left leg	Inferior	P wave positive; QRS positive
	Lead III	Left leg	Inferior	P wave positive, negative or biphasic; QRS positive with lower amplitude in R wave than in lead II
Augmented Limb Leads	aVR	Right arm	None	P wave negative; QRS negative
	aVL	Left arm	Lateral	QRS neutral; neither predominantly positive or negative
	aVF	Left leg	Inferior	QRS upright

(Continued)

Table 1-1 Relationship of Lead Placement Site to Heart Surface and ECG Appearance (*Continued*)

	Lead	Positive Electrode Placement	View of Heart Surface	ECG Appearance
Chest Leads	V ₁	4th intercostal space on right side of sternum	Septum	P wave positive, negative, or biphasic; QRS negative
	V ₂	4th intercostal space on left side of sternum	Septum	P wave positive, negative, or biphasic; QRS biphasic
	V ₃	Midway between V ₂ and V ₄	Anterior	P waves upright; QRS biphasic
	V ₄	5th intercostal space at the midclavicular line on the left	Anterior	P waves upright; QRS biphasic
	V ₅	Midway between V ₄ and V ₆ , level with V ₄	Lateral	P waves upright; QRS upright
	V ₆	Midaxillary line on left, level with V ₄	Lateral	P waves upright; QRS upright

FIVE-STEP INTERPRETATION METHOD

The main rule to interpreting a cardiac rhythm on a monitoring strip or 12-lead ECG is to become boring and repetitive, and to consistently approach the interpretation using the same method. Become a “creature of habit!” A five-step approach is presented here and pulled through the discussions of each of the dysrhythmias to promote easy interpretation and to facilitate memory of the rhythms. When the dysrhythmias are discussed in subsequent chapters, the aspects of the rhythm which vary from normal sinus rhythm are highlighted in red to help with remembering the distinguishing features of the dysrhythmia. Lead II is used as the predominant interpretation lead for this textbook. Interpretation criteria and an ECG strip of normal sinus rhythm are shown here to demonstrate the five-step approach (see Figure 1-9).

1. Rhythm

Analysis of the regularity or irregularity of the rhythm needs to be assessed for the atria and the ventricles. Atrial regularity is evaluated by assessing the consistency of pattern between the P waves. See Figure 1-6 for waveform identification. Are the

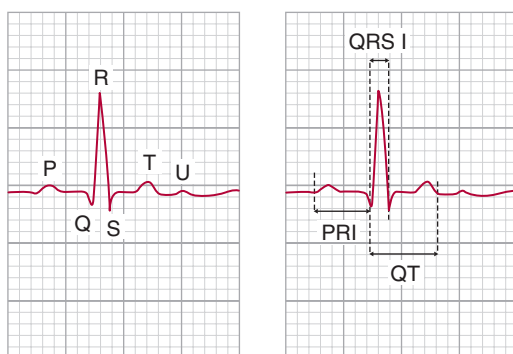


Figure 1-6 ECG waveforms and intervals.

P waves equidistant from each other? Ventricular regularity is evaluated by assessing the consistency of pattern between the R waves. Are the R waves equidistant from each other? Eyeballing the rhythm for regularity may be used initially, but will only help with “grossly” obvious changes in the rhythm. Two more helpful methods are the use of calipers or a paper technique. Calipers are a tool with two needle points hinged together. One needle point is placed at the peak of the P wave or R wave and the second needle point is placed at the peak of the subsequent P wave or R wave. Holding the needle points steady, the calipers are moved down the strip to evaluate the distance between peaks of other subsequent P waves or peaks of subsequent R waves. In regular rhythms the needle points will fall upon the peaks of the P waves for determining atrial regularity or the peaks of R waves for ventricular regularity. If the rhythm is atrially or ventricularly irregular, the needle points of the calipers will not fall at the peaks of the P waves or R waves. The paper technique is accomplished by taking a straight, clean edge of paper, lining it up with the peak of the P waves or R waves, marking on the edge of paper three P wave peaks in a row, moving the paper down to three subsequent P wave peaks, and determining if the P wave marks fit the next three P wave peaks. In regular rhythms, the P wave peak marks will match the subsequent P wave peaks. In irregular rhythms, the P wave markings will not match the location of the P wave peaks on the strip. Repeat the same process with the R waves to determine if the ventricles are beating regularly or irregularly.

2. Rate

Analysis of heart rate needs to be assessed for the atria and the ventricles. What is the atrial heart rate and what is the ventricular heart rate? The heart rates may be evaluated using three different methods: small box, large box, or “quick and dirty.” The small box method is the most accurate, the large box method has the easiest math, and the “quick and dirty” method is used for irregular rhythms. On the ECG grid shown in Figure 1-7, the horizontal axis measures time.

A rapid estimation of rate can be performed using the count-down method. Once the number of small or large boxes has

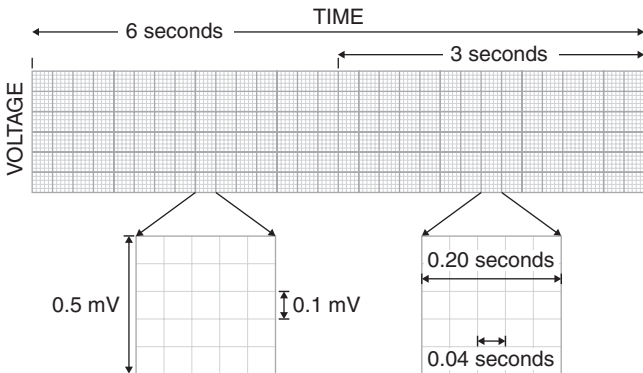


Figure 1-7 ECG grid measurements.

been counted between two sequential P waves or two sequential R waves, the rate can be estimated using the countdown method shown in Table 1-2 or memorizing 300, 150, 100, 75, 60, 50.

Table 1-2 Countdown Method

Large Boxes	Small Boxes	Heart Rate
1	5	300
	6	250
	7	214
	8	188
	9	167
2	10	150
	11	136
	12	125
	13	115
	14	107
3	15	100
	16	94
	17	88
	18	83
	19	79

(Continued)

Table 1-2 Countdown Method (*Continued*)

Large Boxes	Small Boxes	Heart Rate
4	20	75
	21	71
	22	68
	23	65
	24	63
5	25	60
	26	58
	27	56
	28	54
	29	52
6	30	50
	31	48
	32	47
	33	45
	34	44
7	35	43
	36	42
	37	41
	38	39
	39	38
8	40	37

Small Boxes

The small box method is performed by counting the number of small boxes between the peak of two sequential P waves for assessment of atrial rates, and the peak of two sequential R waves for assessment of ventricular rates. Divide the number of small boxes counted into 1,500 to obtain the number of atrial or ventricular beats per minute. For example, 15 small boxes between the peaks of two sequential R waves would give a heart rate of 100 bpm ($1,500/15 = 100$ bpm). See Figure 1-7.

Large Boxes

The large box method is performed by counting the number of large boxes between the peak of two sequential P waves for

assessment of atrial rates, and the peak of two sequential R waves for assessment of ventricular rates. Divide the number of large boxes counted into 300 to obtain the number of atrial or ventricular beats per minute. For example, five large boxes between the peaks of two sequential R waves would give a heart rate of 60 bpm ($300/5 = 60$ bpm). See Figure 1-7.

“Quick and Dirty”

The quick and dirty method should be mainly used when the rhythm is irregular without “funny-looking beats” or extrasystolic beats present within the strip. A “funny-looking beat” or extrasystolic beat is a beat that originates outside the sinus node in the atrial, junctional, or ventricular tissue and occurs every once in a while within the patient’s strip. The quick and dirty technique is done by counting the number of P waves within a 6-second section of the strip and multiplying that number by 10 to give the number of atrial beats per minute. The same technique may be applied to determining the ventricular rate by counting the number of R waves within a 6-second section of the strip and multiplying that number by 10 to give the number of ventricular beats per minute. This method gives an average heart rate. A 6-second strip is the time between three consecutive black lines at the top or bottom of the cardiac monitoring strip (Fig. 1-7). In an irregular rhythm such as in Figure 1-8, the ventricular heart rate is 70 bpm using the “quick and dirty” method.

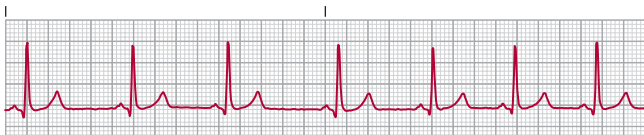

Figure 1-8 “Quick and dirty” assessment of irregular rhythm.

3. P Waves

Analysis of P waves needs to include recognition of a positive or negative deflection from the isoelectric line, consistency of shape, and the actual configuration of the P wave. First, does the

P wave have a positive deflection or extend above the isoelectric line? The isoelectric line is the baseline of the ECG typically located between the T wave and the P wave. A normal P wave is positively deflected or upright (see Fig. 1-6). Second, do all the P waves look alike? Normal P waves are consistent in shape throughout the strip. Third, what is the shape of the P wave? Normal P waves are round in shape. Other shapes of P waves can be notched, tented, inverted, or flattened. Fourth, what is the ratio of P waves to QRS complexes? The normal ratio of P waves to QRS complexes is one to one. Overall, normal P waves are considered to be upright, uniform, and round in a one-to-one ratio with QRS complexes.

4. PR Interval (PRI)

Analysis of the PR interval reflects the length of time taken for the impulse to travel through the AV node. The question to ask is how long is the PR interval? To measure the PR interval, count the number of small boxes between the beginning of the P wave and the beginning of the R wave. Again, one may use either calipers or a paper method. When using calipers, place one needle point of the calipers on the beginning of the P wave and one needle point of the calipers on the beginning of the R wave, hold the calipers steady and move the calipers to a lower point on the ECG strip to more clearly be able to count the number of boxes involved. The paper method involves placing a clean piece of paper under the rhythm, marking the beginning of the P wave and then marking the beginning of the R wave, and moving the paper to a lower point on the ECG strip to more clearly be able to count the number of boxes involved. One small box equals 0.04 seconds in time, and one large box equals 0.20 seconds in time. A normal PRI is 0.12 to 0.20 seconds (see Fig. 1-6).

5. QRS Interval (QRS I)

Analysis of the QRS interval reflects the length of time the impulse takes to depolarize the ventricles. In lead II, the Q wave

is a downward deflection from the isoelectric line lasting less than 0.04 seconds and less than one-third the size of the R wave. The R wave is the first positive or upward waveform after the P wave, and the S wave is the subsequent downward waveform after the R wave. The question to ask is how long is the QRS interval? Again, using calipers or the paper technique, the QRS interval may be measured by marking the beginning of the Q wave to the beginning of the S wave, moving to a lower point on the ECG strip, and counting the number of boxes involved. A normal QRS interval is less than 0.12 seconds. The amplitude or voltage of the R wave is much higher than the P wave because the greater muscle mass in the ventricles can create a larger electrical potential. The amplitude of the R wave can be measured in millivolts on the vertical axis of the ECG grid. Each small box on the vertical axis equals 0.1 mV and every large box on the vertical axis equals 0.5 mV (see Fig. 1-6).

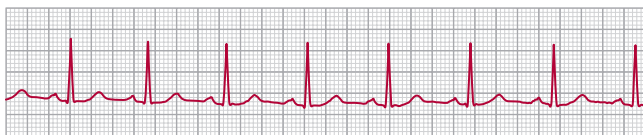

Figure 1-9 Normal sinus rhythm.



Normal Sinus Rhythm Interpretation Criteria

1. Rhythm: regular
2. Rate: 60–100 bpm
3. P wave: upright, uniform, and round in a 1:1 ratio
4. PRI: 0.12–0.20 sec
5. QRS I: less than 0.12 sec

The five-step approach will typically permit ease of interpretation of the many dysrhythmias discussed in this textbook. Keeping a routine to interpreting rhythms makes the skill to be learned similar to tying one's shoes—one step after another. Additional observations are useful for interpreting electrolyte, medication, and myocardial damage.

T Wave

A T wave reflects ventricular repolarization or ventricular muscle relaxation. The T wave is usually upright in leads with an upright R wave, round and slightly asymmetrical with a more gradual slope on the first half of the wave than the second half of the wave. The T wave typically flows in the same direction as the R wave (see Fig. 1-6). Changes in T wave configuration may be seen from electrolyte imbalances, medications, and pulmonary and cardiac issues. For example, an elevated potassium level may cause the T wave to become tented and large; while in myocardial ischemia the T wave may initially be tented, advance to a flattened state, and then become inverted in the leads associated with the myocardial damage.

U Wave

The electrical physiology behind a U wave is not clearly understood. A U wave is a small upright round wave in lead II seen after the T wave and before the next P wave. Although U waves have been seen in normal individuals, the presence of a U wave is more commonly associated with hypokalemia or the administration of medications such as amiodarone or digoxin (see Fig. 1-6).

QT Interval

An interval of time called the QT interval may be measured to reflect the length of time from the beginning of ventricular depolarization to the end of ventricular repolarization, or from the beginning of the Q wave to the end of the T wave. The QT interval is usually called a corrected QT interval or a QTc, because the QT interval is mathematically derived. A normal QT interval varies

by multiple factors including gender, heart rate, and age. The measurement of the QT interval is performed by measuring the distance between two sequential R waves and dividing by two. The second step is to measure the QT interval (Fig. 1-6). A normal QTc is less than one-half of the R-to-R interval (R–R interval), with a borderline issue considered to be about equal to the R–R interval, and an abnormal QTc measuring greater than one-half of the R–R interval. A shortened QT interval may be seen in patients with hypercalcemia, and a prolonged QT interval may be observed in hypocalcemia or with administration of many drugs such as sotalol, phenothiazines, and quinolone antibiotics. A danger associated with prolonged QT intervals is a risk for a more dangerous ventricular rhythm, Torsades de pointes. A QTc of greater than 0.44 second is typically viewed as a concern.

BASIS OF DYSRHYTHMIAS

Dysrhythmias may occur in the SA node, atrial tissue, junctional tissue, AV node, or ventricular tissue. The dysrhythmia may evolve from one of several issues related to electrical impulse flow. The five main types of issues are disturbances with electrical conduction, escape beats/rhythms, enhanced automaticity, reentry mechanisms, and triggered activity. Conduction disturbances are dysrhythmias that occur due to delays or complete blocks of transmission of the electrical impulses such as with AV blocks. Escape rhythms are beats that originate when the rhythm slows down to a point that the atrial, junctional, or ventricular tissue initiates a beat or rhythm at the inherent rate of that tissue. For example, junctional tissue beats at an inherent rate of 40 to 60 bpm (junctional escape rhythm) and ventricular tissue beats at an inherent rate of 20 to 40 bpm (idioventricular rhythm). Enhanced automaticity is the development of a pacemaker site in the atrial, junctional, or ventricular tissue from spontaneous depolarization in those cells or from firing in one of those tissues that overrides the rate of the SA node. Rhythms that may occur from enhanced automaticity are premature atrial contractions, premature junctional contractions, premature ventricular contractions,

atrial flutter, atrial fibrillation, junctional tachycardia, ventricular tachycardia, and ventricular fibrillation. Reentry mechanisms occurs when an electrical impulse circuits back onto itself through a circular conduction route and evolves when the original electrical impulse is slowed or completely blocked from transmitting in its usual pathway. The slowing or complete block of electrical impulse flow results in the impulse circuiting back into the recently depolarized cardiac cells from the initial normal electrical impulse. Reentry mechanisms are rhythms that evolve when electrical impulses are generated during the repolarization of the cardiac cells such as atrial flutter, AV nodal reentrant tachycardia, and many ventricular tachycardias. Triggered activity is due to automaticity of cardiac cells during the repolarization stage in response to a stimulus which causes depolarization. Often referred to as afterdepolarizations, these beats originate from atrial, junctional, and ventricular tissue as single beats, couplets, salvos, and/or runs. Rhythms developing from triggered activity include extrasystolic beats or sustained rhythms such as atrial tachycardia or ventricular tachycardia.

ARTIFACT

When assessing an ECG or cardiac monitoring strip, recognition of patient and monitoring issues becomes essential in an accurate interpretation. Several forms of interference can make waveforms difficult to interpret, such as artifact from patient movement, 60-cycle interference, a wandering baseline, and flatline artifact. Patients connected to cardiac monitoring or a 12-lead ECG can alter the characteristics of the waveforms through movement as simple as washing their face or turning the page of a book (Fig. 1-10). The waveforms created from patient movement may be mistakenly interpreted as ventricular tachycardia, which is the reason to remember to always assess the patient. Sixty-cycle interference may be sensed by the electrodes when leakage from electrically powered equipment occurs. The cardiac telemetry strip may show a QRS wave, but an indistinguishable P wave and isoelectric line. Electrical interference may occur with

excessively moist skin, dried conducting gel on the electrode pads, or placement of electrodes in hairy areas (Fig. 1-11). A wandering baseline may appear if the electrodes have been placed near the patient's diaphragm or if the electrode contact with the skin is not intact (Fig. 1-12). A flat line or no baseline may appear when the patient becomes disconnected to the leadwires or has a leadwire failure or dry electrode gel (Fig. 1-13).

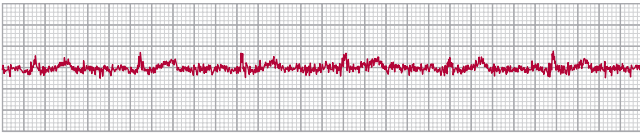


Figure 1-10 Muscular artifact.

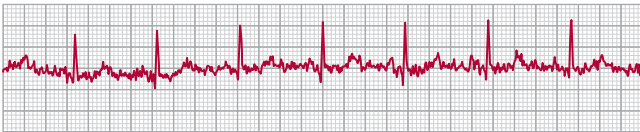


Figure 1-11 60-Cycle electrical interference.

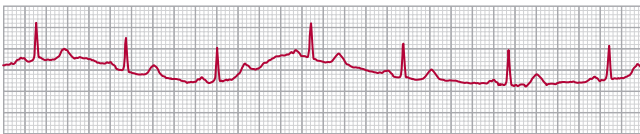


Figure 1-12 Wandering baseline.

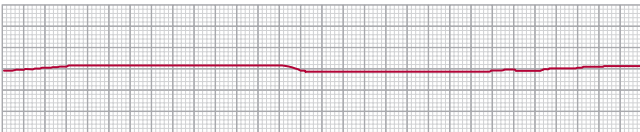


Figure 1-13 Flatline artifact.

